

See discussions, stats, and author profiles for this publication at: <https://www.researchgate.net/publication/383968996>

Assessment of ridge preservation with immediate implant placement using socket shield versus guided bone regeneration techniques in aesthetic zone (a randomized clinical trial)

Article in Alexandria Dental Journal · September 2024

DOI: 10.21608/adjalexu.2023.227285.1405

CITATIONS

0

READS

13

3 authors, including:



Dina Metawie

Alexandria University

5 PUBLICATIONS 0 CITATIONS

SEE PROFILE

ASSESSMENT OF RIDGE PRESERVATION WITH IMMEDIATE IMPLANT PLACEMENT USING SOCKET SHIELD VERSUS GUIDED BONE REGENERATION TECHNIQUES IN AESTHETIC ZONE

(A RANDOMIZED CLINICAL TRIAL)

Faisal S Al Nahdi^{1*} BDS, Hala R Ragab² PhD, Dina M Metawie³ PhD

ABSTRACT

BACKGROUND: The socket shield technique was created to protect periodontal ligament-related perfusion following tooth extraction to prevent alveolar bone resorption, which occurs because of a lack of blood flow caused by the loss of periodontal ligaments.

AIM OF THIS STUDY: was to assess the socket shield method versus guided bone regeneration method for ridge preservation and immediate implant insertion in the upper esthetic zone. Methods: Twenty patients were divided into two groups, group I (control group) received immediate placement of ten dental implants in the maxillary aesthetic zone using the guided bone regeneration technique and group II (study group) received immediate placement of ten dental implants in the socket shield technique. Clinical evaluation of implants stability, pink esthetic score (PES) was done immediately postoperative and after 6 months, and Radiographic evaluation of bone width and marginal bone loss (MBL) was done immediately postoperative and after 6 months.

RESULTS: Regarding implant stability there was a statistically significant difference between the two groups Immediate Postoperative and after 6 months. For the Total pink esthetic score There was a statistically non-significant difference between the two groups Immediate Postoperative and after 6 months. Regarding Bone width There was a statistically non-significant difference between the two group at baseline and after 6 months. For Marginal. Bone level There was a statistically non-significant difference between the two groups at base line and after 6 months.

CONCLUSION: The socket shield Compared to guided bone regeneration seems to be a promising treatment approach for implant in the esthetic zone.

KEYWORDS: Extraction socket, GBR immediate loading, immediate implants, socket shield.

RUNNING TITLE: Immediate implant placement using socket shield in aesthetic zone.

¹ Bachelor of Dental Surgery Riyadh Al Elm University

² Professor of Oral and Maxillofacial Surgery Department, Faculty of Dentistry, Alexandria University, Alexandria, Egypt

³ Lecturer of Oral and Maxillofacial Surgery Department, Faculty of Dentistry, Alexandria University, Alexandria, Egypt

* Corresponding Author:

E-mail: dr.fsn@gmail.com

INTRODUCTION

Tooth extraction can cause variations in the shape of the alveolar ridge. The buccal extraction socket experiences more alveolar ridge resorption than the lingual. In the aesthetic zone, progressive loss of soft and hard tissue can interfere with proper implant placement and affect the overall cosmetic effect of implant-supported prosthesis. Alveolar ridge resorption is a natural consequence of tooth extraction, which can jeopardize the optimal prosthetic placement of dental implants (1-3).

With success rates comparable to those of delayed implant treatments, immediate implant insertion following tooth extraction is a common and effective treatment option. It saves money on procedures and recovery time, but does not prevent alveolar bone loss. Guided bone regeneration (GBR) is often used in the first six months after

extraction to reduce excess bone resorption and speed up the healing process. Although the lack of blood supply from the periodontal ligament may have helped with the unexpected rebuilding process, preserving the alveolar ridge did not improve its condition. Soft tissue volume contraction is often related to the type of surgery performed (4, 5).

A surgical technique called the "socket shield" (SS) approach was developed in 2010 to address the issue of gingival margin location predictability. This technique involves preserving a portion of the root on the buccal side during the initial insertion of the fixture, which protects the periodontium in the marginal region on the buccal side of the implant. The SS approach shows great potential for maintaining the aesthetics of pink and offers a solution for visually challenging problems such as

prominent lip lines. As long as the shield is intact, this procedure not only maintains the tissues but also aids in keeping them healthy in the future (6,7).

Studies comparing socket shield technique to the guided bone regeneration with immediate implant are insufficient that's why the present research was conducted.

Our hypothesis was that using socket shield technique by retaining the labial portion of the root Compared to guided bone regeneration will preserve the hard and soft-tissue and reduce the need for grafting procedures, and the aim of our study was to evaluate of socket shield technique versus guided bone regeneration technique for ridge preservation with immediate implant placement in upper esthetic zone and to compare the differences of the implant stability, pink esthetic score (PES) and marginal bone level (MBL) between both techniques.

MATERIALS AND METHODS

Study design

This was a randomized controlled clinical trial, with group I & group II with 1:1 allocation ratio. In accordance with the CONSORT standards, the research was reported. (<http://www.consortstatement.org>) ethical approval no.0470-07/2023

Type of Intervention

- The study group: Utilizing the socket shield approach, ten of the front teeth in the maxilla were removed and then immediately replaced with implants.
- The control group: Ten of the front teeth in the maxilla were removed, and then implants and guided bone regeneration (GBR) using a bone replacement made from bovine origin (RE-BONE®) were placed right away.

Sample size calculation

Based on previously treated trial cases (8) (Pink Esthetic Score), we conducted a power analysis (G power version 3.1 statistical software, Franz Faul, Universität Kiel Germany). *A priori* analysis was performed to compute the required sample size-given α , power, and effect size. The input parameters were α error probability of 0.05, an effect size (f) of 1.6, a power of 0.95 and number of groups was 2. The findings indicated a minimum sample size of $n = 18$ samples, (9 samples for each group). Considering a possible loss of about 10 % of patients, we used 20 samples, (10 samples for each group).

Eligibility criteria

Participants enrolled in the study were selected after fulfilling the following criteria:

Inclusion Criteria

- Nonrestorable maxillary anterior teeth in the esthetic zone.
- Intact buccal plate of bone.
- Healthy periodontal condition.
- Intact root with no mobility in the tooth and no subgingival caries.
- Good oral hygiene.
- Patients of both genders.

Exclusion Criteria

- Periodontal disease-affected teeth
- Teeth having external or internal root resorption or local pathologic events affecting the labial area of the root were excluded. Vertical root fractures and horizontal fractures at or under the bone level were also disqualifying.
- Patients who suffer from systemic conditions like uncontrolled diabetes mellitus that might hinder their body's natural ability to recover.
- A history of head and neck radiation treatment.
- A history of parafunctional behaviors or bruxism.
- Pregnant and lactating mother.

Materials

1. Dental implant system (ROOTT implant system).
2. High-speed handpiece (Sirona T3 Racer Highspeed).
3. Bone substitute of bovine origin (RE-BONE® Hygitech, UK).
4. Cone beam computed tomography (CBCT) scans (Planmeca promax 3D, Planmeca, Finland).
5. Long-shanked round diamond bur (Komet Dental, Germany).

A. Preoperative phase

Pre-operative clinical examination has been performed on every patient: the patient's name, sex, age, and medical and dental histories were also obtained. preoperative 3D CBCT for implant surgical planning and proper studying of the case was done.

B. Surgical phase (6)

Plaque-control strategies and oral hygiene advice were given to the patients. The patients were instructed to just before to surgery rinse their mouths with mouthwash containing chlorhexidine HCL 1.25%. All operations employed local infiltration anesthesia.

In group I, teeth were decoronated with a high-speed handpiece and diamond bur while being fully irrigated, at a height of one millimeter above the gum line. Utilizing light, sweeping strokes from the gum line to the root apex, the Lindemann bur was employed to delicately separate the facial root segments from the remaining root. the periodontal ligaments connecting the palatal root section to the palatal alveolar plate were severed employing a tiny periosteal elevator. After the split palatal component was carefully removed without damaging the intact labial segment. Using a long-shanked round diamond bur, the shield contour was thinned in the mesiodistal and apical-coronal directions, and the coronal section of the labial segment was reduced almost to the level of the alveolar crest. We followed the manufacturer's directions and implanted the device. **Figure (1)**

In group II, Atraumatic extraction was done to minimize damage to the remaining alveolar bone. Curettes were then utilized to carefully clean the

socket, and physiological saline solution was utilized to irrigate the area after the tooth had been extracted. Following palatal osteotomy, there was a two-millimeter gap between the implant & the labial plate. Apically to the bone crest, the implant was positioned two to three millimeters away. RE-BONE®, a bone replacement, filled the space **Figure (2)**. Both groups received treatment from a healing abutment. A customized healing abutment to support a coronal natural emergence profile of the tooth. For esthetic issues, a provisional cement retained resin-bonded crown was fabricated and cemented after 6 months.

Postoperative phase

On day one, participants were told to apply cold compresses as needed, at least once every ten minutes for an hour. Both an oral antibiotic (1 g every 12 hours for five days) and an oral analgesic (400 mg every eight hours for five days) were prescribed to be taken after surgery. Patients were also instructed to practice strict oral hygiene practices and to regularly rinse with chlorhexidine 0.2% mouthwash for two weeks.

Follow up phase

Clinical evaluation

Measurement of implants stability (9)

Implant stability was assessed for each participant group at the time of implant placement (primary stability) as well as after a period of six months using resonance frequency analysis (RFA) using the Osstell ISQ system. The average value of each implant's mesiodistal and buccolingual measurement was determined after it was measured twice for each direction.

Pink esthetic score (PES) (10)

The pink esthetic score (PES) assesses the esthetic result of soft tissue surrounding single crowns that are supported by implants in the anterior zone. Points are awarded for mesial and distal papilla, soft-tissue color, soft-tissue texture, soft-tissue level, soft-tissue contour & alveolar process deficiency.

Radiographic evaluation

Every individual have CBCT scans right after surgery and again at 6 months to evaluate bone width and marginal bone loss (MBL) **Figure (3,4)**.

C. Prosthetic phase

After waiting for six months, a prosthodontist completed the final prosthetic procedure (a porcelain bonded to metal crown) **Figure (5,6)**.

Statistical analysis of the data: The IBM SPSS software application, version 20.0, was utilized to do the analysis once the data had been entered into the computer. Armonk, New York location of IBM Corporation. In order to validate the assumption that the distribution was normal, the Shapiro-Wilk test was carried out. Quantitative information was summarized utilizing mean and standard deviation. Results were considered significant at the 5% level.

The Student t-test, Paired t-test, and ANOVA were utilized.

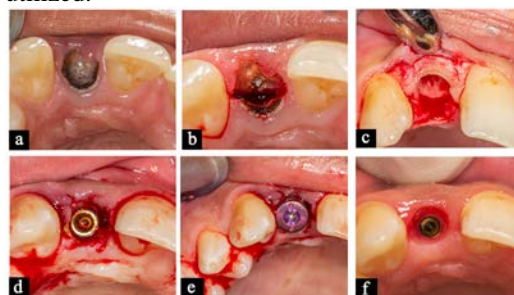


Figure 1: Socket shield technique procedure.

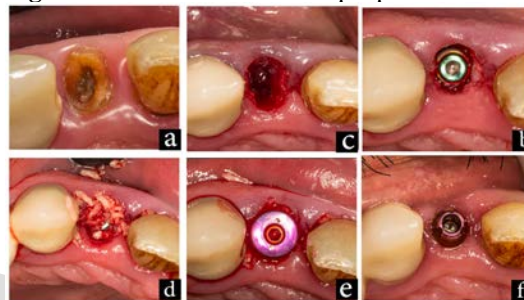


Figure 2: Guided bone regeneration procedure.

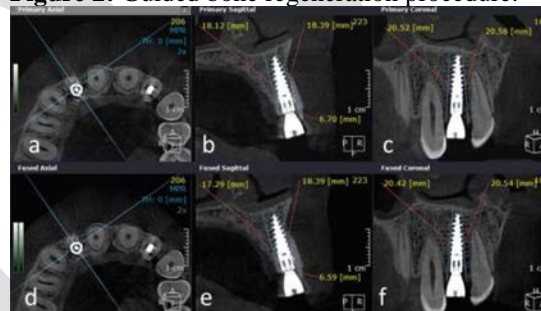


Figure 3: Socket shield technique: immediately post operative, **a)** implant in site in axial plan, **b)** MBL buccal and palatal and bone width in sagittal plan, **c)** MBL buccal and palatal and bone width in coronal plan. At 6 months, **d)** implant in site in axial plan, **e)** MBL buccal and palatal and bone width in sagittal plan, **f)** MBL buccal and palatal and bone width in coronal plan.

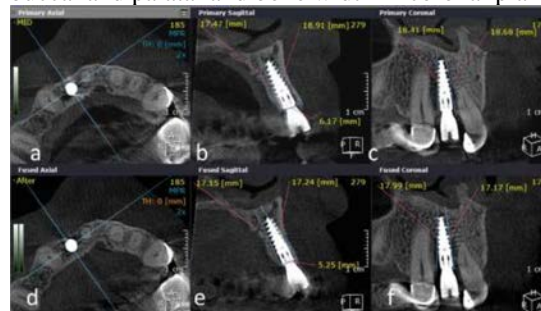

Figure 4: Guided bone regeneration immediately post operative, **a)** implant in site in axial plan, **b)** MBL buccal and palatal and bone width in sagittal plan, **c)** MBL buccal and palatal and bone width in coronal plan. At 6 months, **d)** implant in site in axial plan, **e)** MBL buccal and

palatal and bone width in sagittal plan, f) MBL buccal and palatal and bone width in coronal plan.

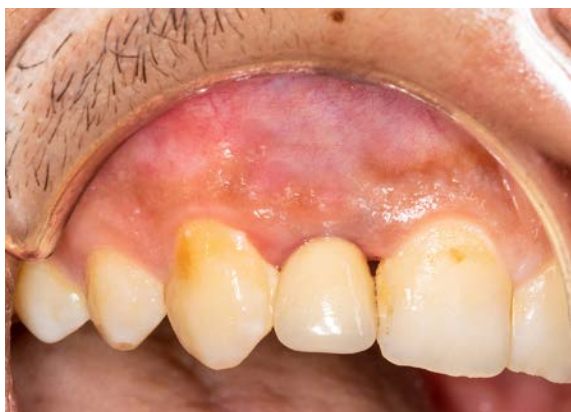

Figure 5: The final restoration was fabricated for patient after 6 months in the socket shield technique.

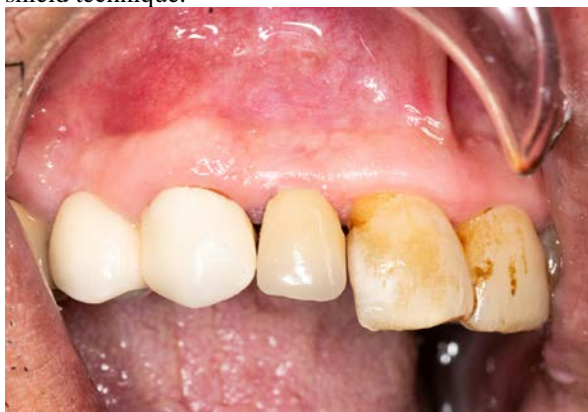

Figure 6: The final restoration was fabricated for patient after 6 months in the guided bone regeneration technique.

RESULTS

Shield technique to guided bone regeneration

Comparison between the two groups according to demographic data. Socket shield technique group had 4 (40%) male and 6 (60%) females while guided bone regeneration group had 10 (100%) males. The difference was significant. Table (1). Regarding age the mean age of the the patient's in Socket shield technique group was 31.40 ± 5.12 while that of he guided bone regeneration was 34.90 ± 3.28 . the difference was non-significant Table (1).

Regarding implant stability there was a statistically significant difference between the two groups Immediate Postoperative and after 6 months ($p=0.001^*$ and 0.019^*) respectively. Table (2).

Regarding Total pink esthetic score there was a statistically non-significant difference between the two groups Immediate Postoperative and after 6 months ($p=0.344$ and 0.647) respectively Table (2).

Regarding Bone width there was a statistically non-significant difference between the two group at baseline and after 6 months ($p=0.662$ and 0.121) respectively. Socket shield technique showed a lower Change from Immediate Postoperative than guided bone regeneration at baseline and at six months Table (3).

Regarding marginal bone level there was a statistically non-significant difference between the two groups at baseline and after 6 months ($p=0.844$ and 0.809) respectively Table (3).

Table (1): Comparison among the two groups according to demographic data.

	Socket shield	Guided bone regeneration	t	p
Age	31.40 ± 5.12	34.90 ± 3.28	1.189	0.086
Gender	Male 4 (40%) Female 6 (60%)	Male 10 (100%) Female 0 (00%)	X ² =8.571	0.003*

t: Student t-test

p: p value for comparing among the two examined groups.

X²= qui square

Table (2): Clinical results comparison between the two groups according the implant stability and total pink esthetic score.

	Socket shield	Guided bone regeneration	t	p
Implant stability				
Baseline	76.67 ± 4.04	49.33 ± 2.89	9.532	0.001*
After 6 months	82.0 ± 2.65	75.0 ± 1.73	3.834	0.019*
Total pink esthetic score				
Immediate postoperative	8.50 ± 0.66	9.31 ± 1.13	1.073	0.344
After 6	9.70 ± 0.77	9.30 ± 1.14	0.494	0.647

Data was expressed using Mean \pm SD. SD: Standard deviation
t: Student t-test

p: p value for comparing between the two studied groups

*: Statistically significant at $p \leq 0.05$

Table (3): Radiographic results comparison between the two studied groups according marginal bone level and bone width.

	Socket shield	Guided bone regeneration	t	p
Bone width				
Baseline	6.36 ± 0.95	6.13 ± 0.16	0.460	0.662
After 6 months	6.27 ± 0.93	5.39 ± 0.28	1.806	0.121
Change from Baseline	0.08 ± 0.05	0.74 ± 0.32	3.977	0.007*
Average Marginal bone level				
Baseline	18.38 ± 2.10	18.06 ± 2.26	0.206	0.844
After 6 months	18.40 ± 1.94	18.03 ± 2.10	0.253	0.809
Change from Baseline				
After 6 months	0.17 ± 0.16	0.02 ± 0.16	0.370	0.724

Data was expressed using Mean \pm SD. SD: Standard deviation t: Student t-test
 p: p value for comparing between the two studied groups

DISCUSSION

Retaining the buccal part of the root allows for the preservation of periodontal vascularization, which reduces socket resorption without the use of any grafting materials or other regenerative techniques and reduces the cost and potential number of surgical interventions while requiring a minimum of invasiveness and producing the best aesthetic result (11).

In order to prevent tissue changes after tooth extraction, Hürzeler et al. (6) proposed a novel approach in 2010 called the socket shield technique, in which a partial root fragment was kept around an implant that was inserted right away. The periodontal ligament's maintenance of the root will keep the extraction socket's physiologic remodeling at a safe distance. An essential biological adjustment following tooth extraction might be defined as marginal bone loss and subsequent modifications in the soft tissues (12).

The current study evaluated the implant stability using A resonance frequency analyzer which has been reported to be a reliable tool for this purpose. Regarding implant stability: There was a statistically significant difference between the two groups immediately postoperative and after 6 months respectively. Socket shield technique showed a higher implant stability than guided bone regeneration. These results are in line with the systematic review and meta-analysis by Scarano et al., (11) where the immediate implants placed with socket shield technique had a statistically significant increase in implant stability compared to other implant placement protocols without socket shield technique. The authors suggested that the socket shield technique could enhance the functional and esthetic results by preserving the alveolar bone and peri-implant soft tissues.

In the present study, Regarding Total pink esthetic score: There was a statistically non-significant difference between the two groups immediate Postoperative and at 6 months respectively. Similar results were obtained by Bramanti et al. (12) concluded that the socket-shield technique is a safe surgical technique that allows for dental implant rehabilitation characterized by better aesthetic outcomes. One of the possible reasons for this outcome might be attributed to the maintenance of the vascular support provided by the periodontal ligament maintained to the tooth root portion left in situ.

In agreement with our results, Velasco et al., (13) compared, pink esthetic score for the socket-shield

technique and the conventional technique for immediate dental implant placement in the esthetic zone. Dental implant failure rate did not differ between the socket-shield technique and conventional technique for immediate implant placement in the esthetic zone. Gao et al., (14) systematically reviewed and analyzed the efficacy of the socket shield technique in conjunction with immediate implant placement in the aesthetic zone in randomized controlled trials. The findings suggest that the socket shield technique has the potential to maintain buccal tissue contours and peri-implant tissue stability, improving functional and aesthetic outcomes in the aesthetic zone compared with the conventional immediate implant placement technique.

The socket shield technique seems to have positive effects on the changes in the width and height of buccal bone plate, peri-implant marginal bone levels and esthetic outcomes as demonstrated by significantly less changes in bone levels and higher pink esthetic score at different time points.

Regarding Bone width: There was a statistically non-significant difference between the two groups at baseline and after 6 months. Socket shield technique showed a lower Change from Immediate Postoperative than guided bone regeneration. Abd-Elrahman et al., (8) compared the vertical and horizontal changes of the buccal cortical bone plates, encountered after utilizing the socket shield technique with immediate temporization vs an immediate implant placement with immediate temporization, between both techniques he concluded that the socket shield technique with immediate temporization is a reliable method to reduce changes in the width of buccal bone plate, following teeth extraction. Barakat et al. (15) in a randomized controlled trial compared conventional immediate implant placement and SST and reported that the mean horizontal and vertical bone loss value in SST was 0.09 ± 0.03 mm and 0.43 ± 0.23 mm contrary to 0.33 ± 0.14 mm and 1.56 ± 0.77 mm in the conventional implantation. Which is consistent with the results obtained by the present study.

Sun et al. (16) in a randomized controlled trial reported higher buccal plate width (1.15 ± 0.27 mm) and buccal plate height (2.59 ± 0.21 mm) values in SST group as compared to the control group (bone plate width = 0.83 ± 0.13 mm and bone plate height = 1.82 ± 0.18 mm) after 6 months of implant placement. They concluded that SST may improve functional and esthetic outcomes by maintaining alveolar bone volume and peri-implant tissues. Tiwari et al., (17) aimed to compare the efficacy of immediate implant placement after extraction without socket-shield technique and with socket-shield technique in the esthetic region. They concluded that the two techniques need further comparison contrary to the results obtained by our

study which demonstrated better preservation of bone through the socket-shield technique, thus eliminating the need for any bony substitutes.

CONCLUSION

The socket shield Compared to guided bone regeneration seems to be a promising treatment approach for implant in the esthetic zone.

CONFLICT OF INTEREST

The authors declare that they have no conflicts of interest.

FUNDING STATEMENT

The authors received no specific funding for this work.

REFERENCES

1. Donati M, Ekestubbe A, Lindhe J, Wennström JL. Implant-supported single-tooth restorations. A 12-year prospective study. *Clin Oral Implants Res.* 2016;27:1207-11.
2. De Angelis N, Signore A, Alsayed A, Hai Hock W, Solimei L, Barberis F, Amaroli A. Immediate Implants in the Aesthetic Zone: Is Socket Shield Technique a Predictable Treatment Option? A Narrative Review. *J Clin Med.* 2021;10:4963.
3. Mello CC, Lemos CAA, Verri FR, Dos Santos DM, Goiato MC, Pellizzer EP. Immediate implant placement into fresh extraction sockets versus delayed implants into healed sockets: A systematic review and meta-analysis. *Int J Oral Maxillofac Surg.* 2017;46:1162-77.
4. Sato R, Matsuzaka K, Kokubu E, Inoue T. Immediate loading after implant placement following tooth extraction up-regulates cellular activity in the dog mandible. *Clin Oral Implants Res.* 2011;22:1372-8.
5. Siormpas KD, Mitsias ME, Kotsiotou-Siormpa E, Garber D, Kotsakis GA. Immediate implant placement in the esthetic zone utilizing the "root-membrane" technique: clinical results up to 5 years postloading. *Int J Oral Maxillofac Implants.* 2014;29:1397-405.
6. Hürzeler MB, Zuhr O, Schupbach P, Rebele SF, Emmanouilidis N, Fickl S. The socket-shield technique: a proof-of-principle report. *J Clin Periodontol.* 2010;37:855-62.
7. Kumar PR, Kher U. Shield the socket: Procedure, case report and classification. *J Indian Soc Periodontol.* 2018;22:266-72.
8. Abd-Elrahman A, Shaheen M, Askar N, Atef M. Socket shield technique vs conventional immediate implant placement with immediate temporization. Randomized clinical trial. *Clin Implant Dent Relat Res.* 2020;22:602-11.
9. Abadzhiev M, Nenkov P, Velcheva P. Conventional immediate implant placement and immediate placement with socket-shield technique – which is better. *Int J Clin Med Res.* 2014;1:176-80.
10. Morton D, Chen ST, Martin WC, Levine RA, Buser D. Consensus statements and recommended clinical procedures regarding optimizing esthetic outcomes in implant dentistry. *Int J Oral Maxillofac Implants.* 2014;29(Suppl):216-20.
11. Saeidi Pour R, Zuhr O, Hürzeler M, Prandtner O, Rafael CF, Edelhoff D, Liebermann A. Clinical Benefits of the Immediate Implant Socket Shield Technique. *J Esthet Restor Dent.* 2017;29:93-101.
12. Lang NP, Pun L, Lau KY, Li KY, Wong MC. A systematic review on survival and success rates of implants placed immediately into fresh extraction sockets after at least 1 year. *Clin Oral Implants Res.* 2012;23(Suppl 5):39-66.
13. Velasco Bohórquez P, Rucco R, Zubizarreta-Macho Á, Montiel-Company JM, de la Vega Buró S, Madroño EC, et al. Failure Rate, Marginal Bone Loss, and Pink Esthetic with Socket-Shield Technique for Immediate Dental Implant Placement in the Esthetic Zone. A Systematic Review and Meta-Analysis. *Biology (Basel).* 2021;10:549.
14. Gao B, Lai X, Dong Y, Li X. Clinical efficacy of the socket shield technique used in the aesthetic zone: A systematic review and meta-analysis. *Int J Oral Implantol (Berl).* 2022;15:45-55.
15. Barakat DA, Hassan RS, Eldibany RM. Evaluation of the socket shield technique for immediate implantation. *Alex Dent J.* 2017;42:155-61.
16. Sun C, Zhao J, Liu Z, Tan L, Huang Y, Zhao L, et al. Comparing conventional flap-less immediate implantation and socket-shield technique for esthetic and clinical outcomes: A randomized clinical study. *Clin Oral Implants Res.* 2020;31:181-91.
17. Tiwari S, Bedi RS, Wadhwani P, Aurora JK, Chauhan H. Comparison of immediate implant placement following extraction with and without socket-shield technique in esthetic region. *J Maxillofac Oral Surg* 2020;19:552–60.