

# The added value of the pterygoid implant in the management of edentulous patients

Dr Henri Diederich, Luxembourg

**Pterygoid implants** were first proposed by Linkow in 1975, and the method was first described by French maxillofacial surgeon J.F. Tulasne in 1992.<sup>1,2</sup> Tulasne and Tessier were the first to describe the technique for implant placement in the pterygoid plate. Pterygoid implants are relatively long and specifically manufactured with the characteristics of the pterygoid region in mind.<sup>3</sup>

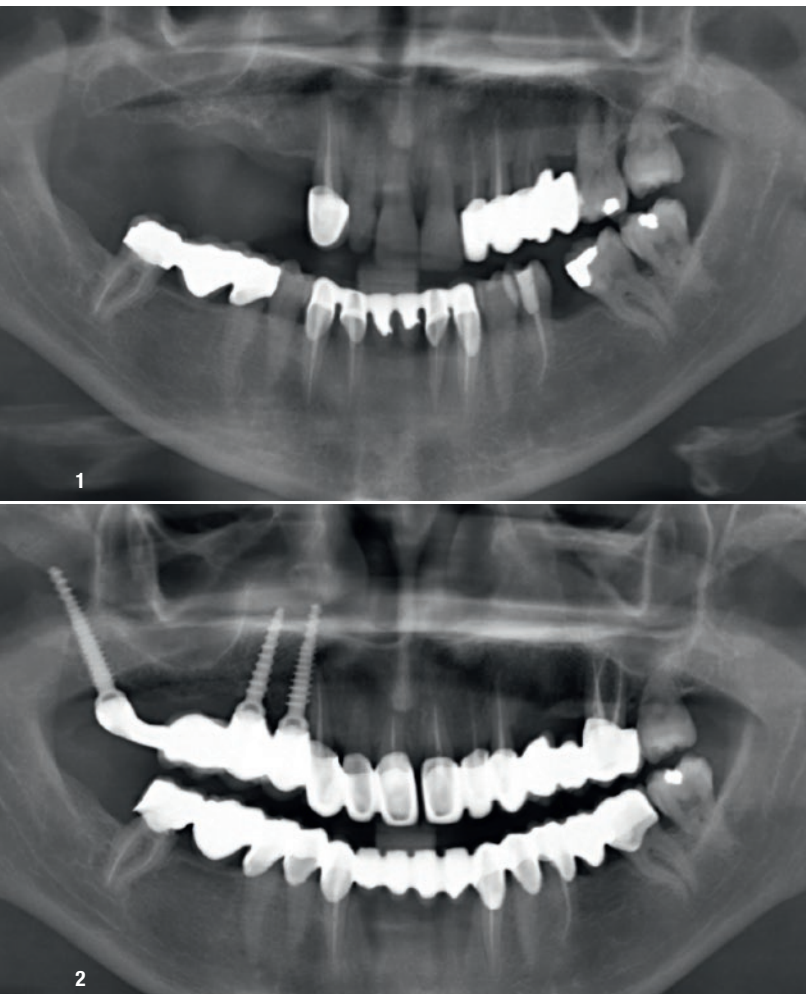
The pterygoid implant enables rehabilitation in the posterior maxilla in cases of poor and limited bone quantity as well as the presence of the maxillary sinus when such cases cannot be treated with standard implants.<sup>4-6</sup> Expertise and a thorough understanding of the anatomy of the posterior maxilla are crucial for successful placement of pterygoid implants. The pterygoid implant placement method has been previously documented in the literature.<sup>7</sup>

The following case studies showcase the use of pterygoid implants to restore function in patients with edentulous jaws. The pterygoid implant employed in this case series is a new generation of pterygoid implant, designed by the author in collaboration with the Swiss company TRATE. It is a one-piece tissue-level conical implant with compressive threads and undergoes a surface treatment with hydroxyapatite and tricalcium phosphate. The implant neck has a wide thread profile, providing compression in areas of low bone density, such as the maxillary tuberosity. Its pointed, self-tapping apex ensures strong anchorage when inserted.<sup>3,8</sup> The pterygoid implant ranges from 16 to 26 mm in length, ensuring that the implant apex engages the cortical bone of the medial wall of the pterygoid plate<sup>9</sup> and is 3.5 or 4.5 mm in diameter.

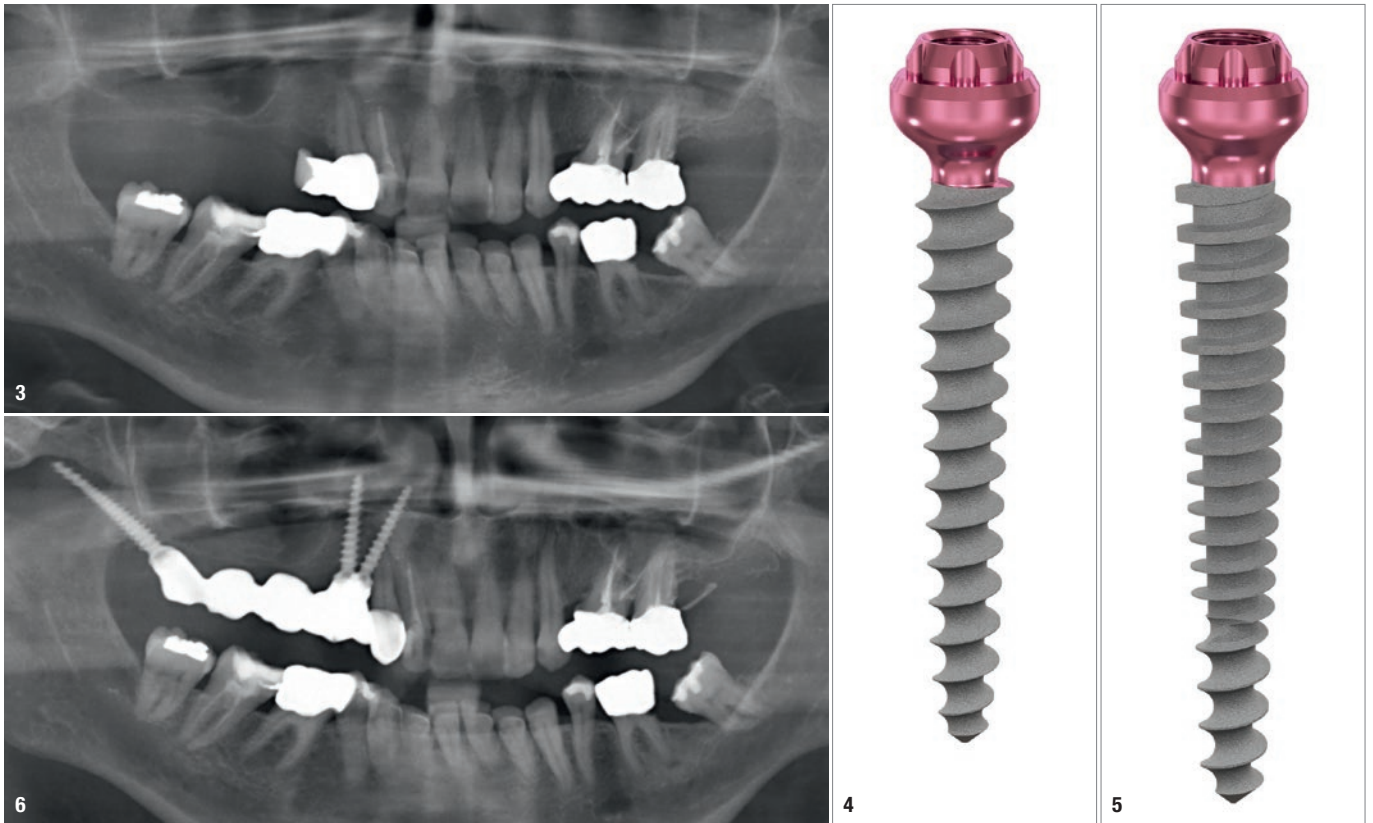
## Case presentations

### Case 1

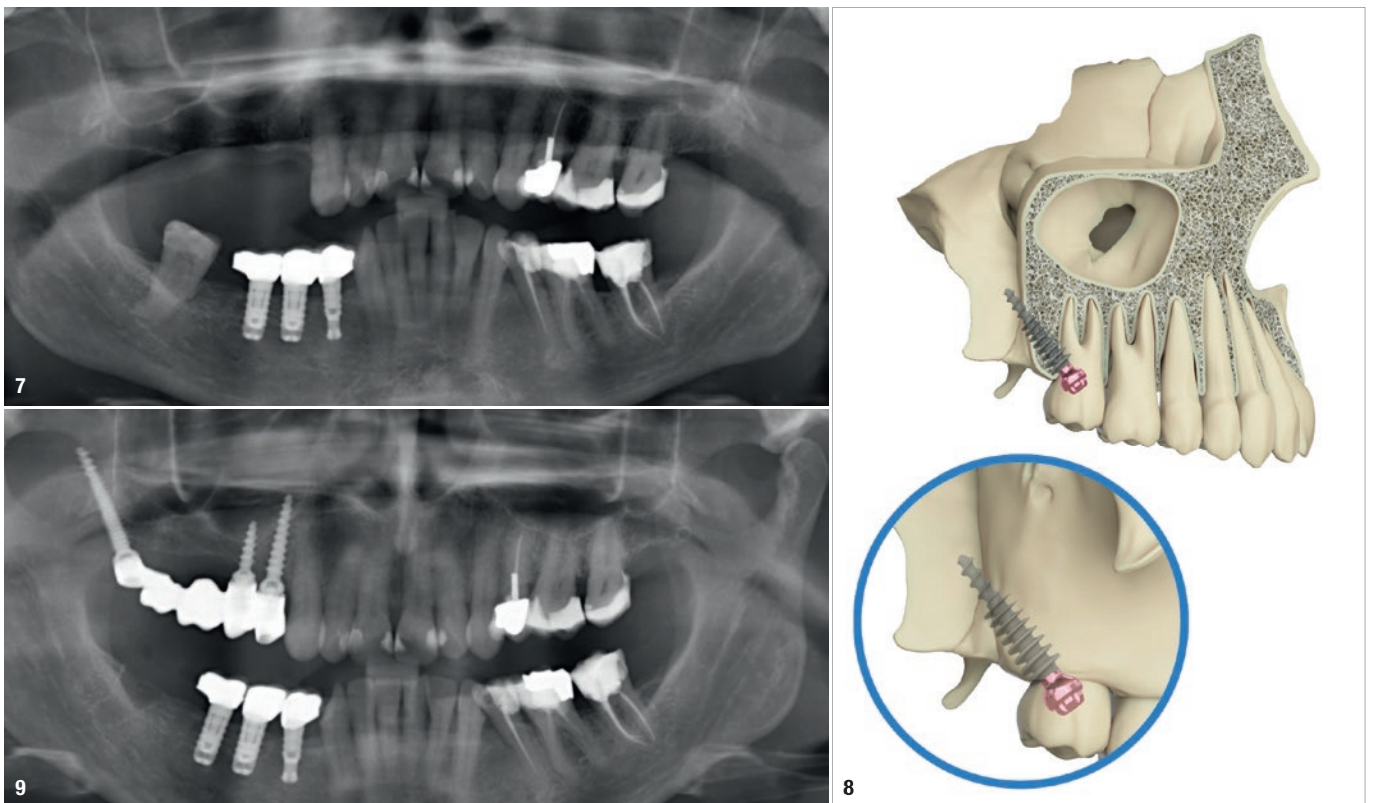
A 45-year-old female patient sought to have missing teeth on the right side of her upper jaw replaced (Fig. 1). Owing to the narrow width of the upper jaw ridge, conventional implant options were not feasible. The patient also had a history of chronic sinus infection and did not wish to undergo a sinus lift procedure. To rehabilitate her missing teeth, ROOTT C3516m, C3514m and C3520mp implants were placed in positions #18, 15 and 14. The procedure was performed under local anaesthesia after flap elevation, and a 2.5 mm pilot drill was used to prepare all three osteotomies. The implants were loaded after a three-month delay, and a screw-retained metal–ceramic bridge



**Fig. 1:** Case 1—panoramic radiograph of the patient at presentation. **Fig. 2:** Radiograph of the patient after bridge delivery.



**Fig. 3:** Case 2—panoramic radiograph of the patient at presentation. **Figs. 4 & 5:** Traditional implant options were not feasible owing to the narrow ridge. ROOTT C3016ms implants were placed in positions. **Fig. 6:** Radiograph of the patient after bridge delivery.



**Fig. 7:** Case 3—panoramic radiograph of the patient at presentation. **Fig. 8:** Placement of pterygoid implant into the maxilla. **Fig. 9:** Radiograph of the patient after bridge delivery.

was seated 14 days after impression taking with screwed impression copings (Fig. 2).

**Case 2**

The next case involved a 64-year-old female patient who sought to have missing teeth on the right side of her upper jaw replaced (Fig. 3). The patient had extensive maxillary sinus pneumatisation and a narrow alveolar ridge. Owing to her history of chronic sinus infection, a sinus lift procedure was not a desired option. Traditional implant options were not feasible owing to the narrow ridge. ROOTT C3016ms implants were placed in positions #15 and 14 (Figs. 4 & 5). The patient received an immediate temporary bridge constructed at the chairside after the surgery (Fig. 6). Three months after the surgery, impressions were taken with screwed impression copings, and a screw-retained metal bridge was seated three weeks later.

**Case 3**

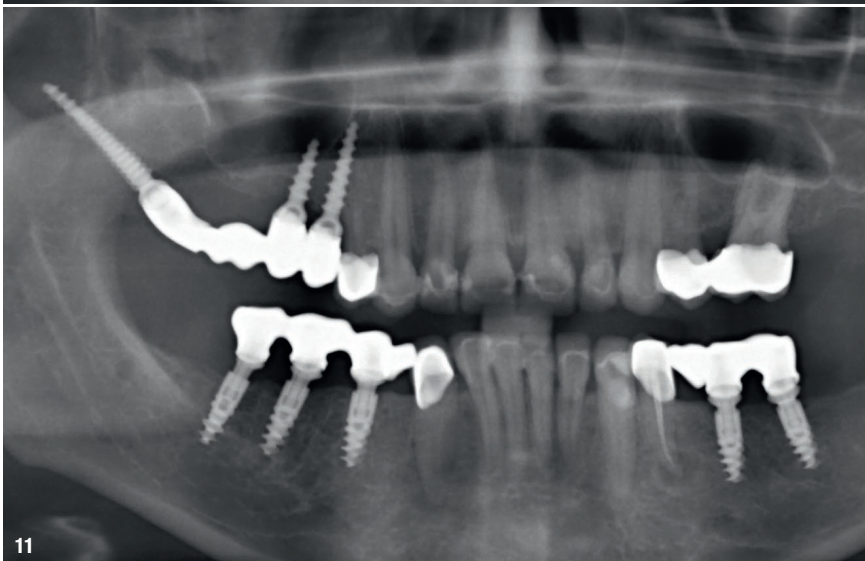
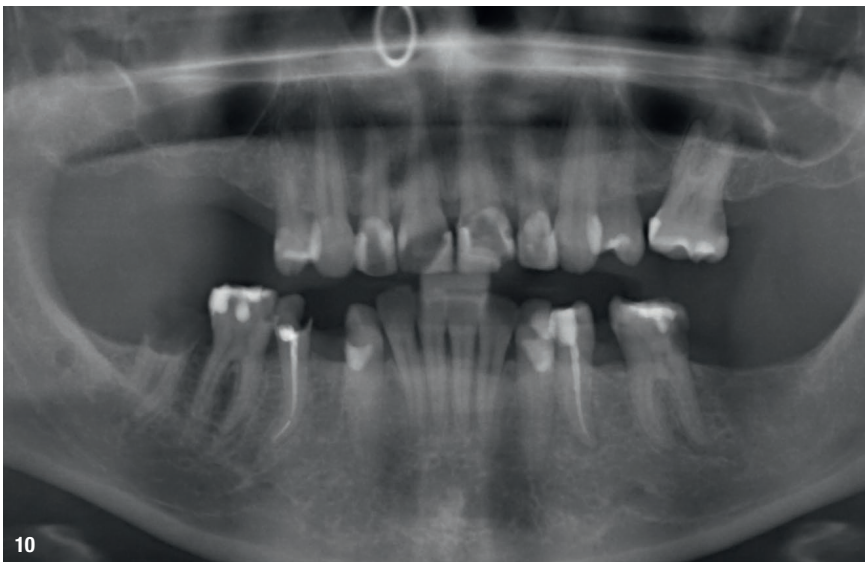
In a similar case, a 54-year-old female patient sought a solution for missing teeth on the right side of her upper jaw (Fig. 7). ROOTT C3514m, C3008ms and C3520mp implants were placed in positions #18, 15 and 14 (Figs. 8 & 9).

**Case 4**

A 34-year-old female patient presented with missing teeth in her right upper jaw (Fig. 10). A similar treatment approach was taken to that used in the previous cases, involving the placement of ROOTT C3512m, C3508m and C3520mp implants in positions #18, 15 and 14 (Fig. 11).

**Case 5**

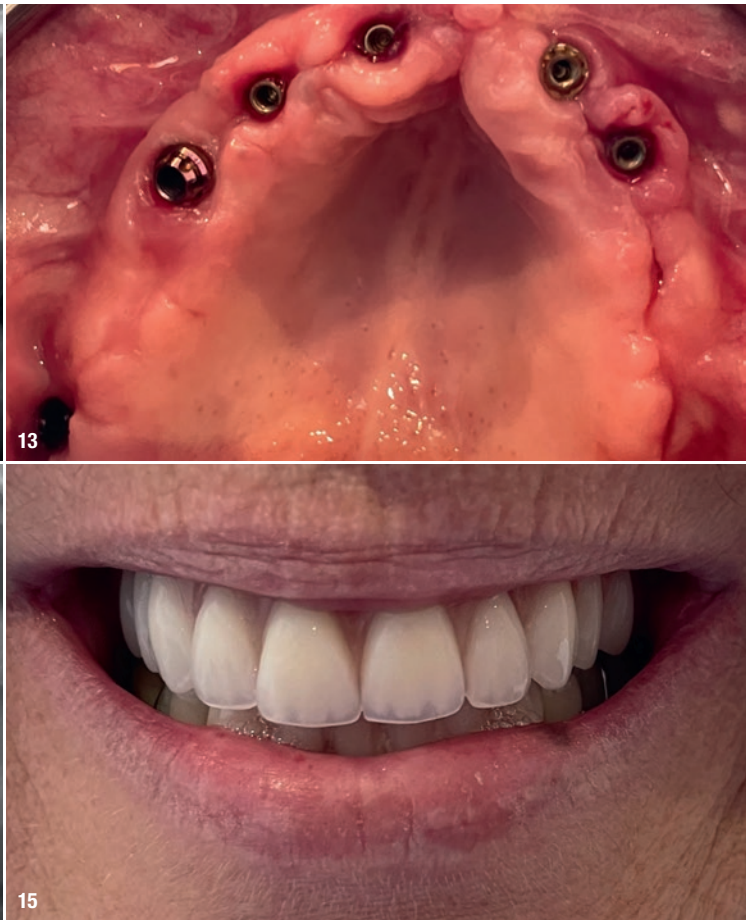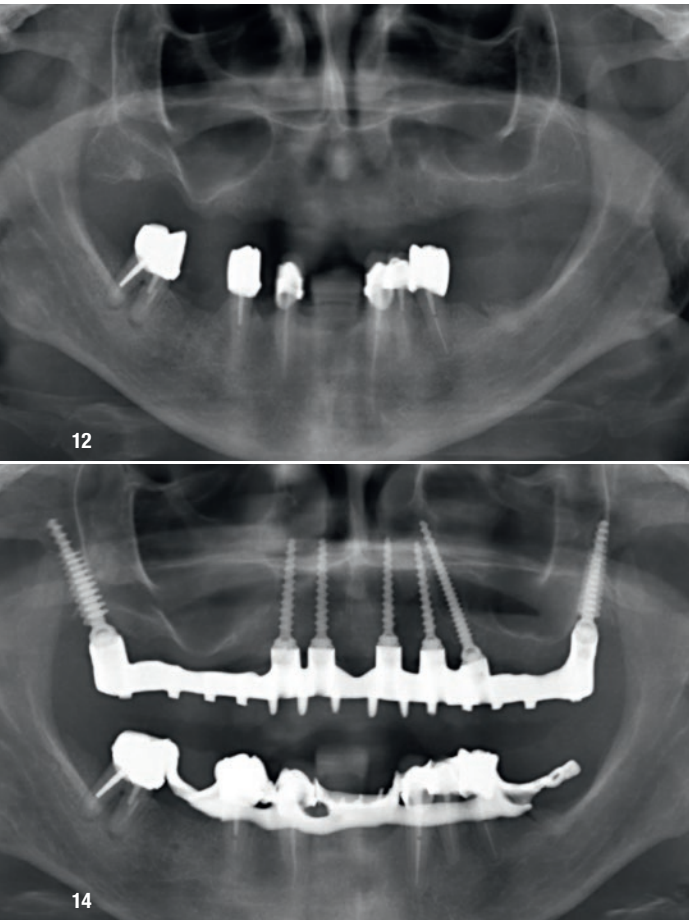
A 54-year-old female patient sought to have her complete denture replaced with a fixed solution, without undergoing extensive surgical procedures such as bone grafting or sinus lift (Fig. 12). Owing to her narrow alveolar ridge, it was decided to use standard one-piece tissue-level implants and pterygoid implants for rehabilitation of the upper jaw. The procedure was performed under local anaesthesia after flap elevation. A 2.5 mm pilot drill was used for preparation of all the osteotomies. ROOTT C4520mp implants were placed in positions #18 and 28, ROOTT C3016ms implants with short necks were placed in positions #13, 12, 22 and 23, and a ROOTT C3522mp implant was placed in position #24 (Fig. 13). Early loading was carried out with a temporary denture fabricated at the chairside (Fig. 14). After five days, the key was tried in. One week later, a trial of the metal frame was done, and a further week later, an aesthetic trial was conducted. At the fourth appointment, the metal–resin denture was screwed in (Fig. 15). The patient left the clinic with a fixed solution without having to undergo extensive surgical procedures.



**Fig. 10:** Case 4—panoramic radiograph of the patient at presentation. **Fig. 11:** Radiograph of the patient at the completion of treatment.

**Discussion**

These case reports demonstrate the use of pterygoid implants for restoration of the maxilla in various cases. With this approach, atrophic jaws could be rehabilitated without the need for additional surgical procedures such as sinus lift and bone grafting.<sup>1</sup> The use of pterygoid implants allows for the resolution of many cases that cannot be managed with standard implants within a short period, effectively solving the patients' problem of edentulism.<sup>3,6,8,10–12</sup> The high success rates of pterygoid implants in patients with minimal bone levels and minimal complications make them an attractive option for treating such patients.<sup>6,13,14</sup>



**Fig. 12:** Case 5—panoramic radiograph of the patient at presentation. **Fig. 13:** Healed situation after pterygoid implant placement in the maxilla. **Fig. 14:** Radiograph of the patient at the completion of treatment. **Fig. 15:** Clinical photograph of the patient at the completion of treatment.

### about the author



**Dr Henri Diederich** is a highly accomplished dentist with over 35 years of experience. He received his doctorate in dentistry from the Free University of Brussels (ULB) in 1985, after which he established his own successful dental clinic in Luxembourg. As a Sworn Expert at the Luxembourgish Court of Justice, Dr Diederich has gained a reputation as

a leading authority in legal dentistry. He is also the founding member and President of the Implantoral Club Luxembourg and President of the Open Dental Community. In addition to his extensive involvement in professional organisations, Dr Diederich has also held the position of Maître de stage at the University of Nancy, France, and is responsible for regular training seminars for the management of implantation in atrophied bone at Queen Mary University in London. Dr Diederich is a renowned international lecturer and has published numerous papers on immediate loading in atrophied bone. He is the inventor of the CF@O protocol and the Hybrid Plates HENGG-1/4, for which he holds patents (Nr 93019 and 93186).

His memberships in various professional organisations, including ICOI, DGOI, BDIZ EDI, DGZMK, and BAFO, attest to his dedication and expertise in the field of dentistry.



### contact

**Dr Henri Diederich**  
+352 621 144664  
hdidi@pt.lu